



**PATIENT**

Quinn Dougherty

**SPECIES**

Canine

**BREED**

Miniature Dashchund

**SEX**

Female Intact

**AGE**

10 months

**WEIGHT**

8.8lbs

**INTERPRETED BY**

Maggie Machen Lamy,  
DVM, DACVIM  
(Cardiology)

**IMAGING PERFORMED BY**

Renee Trionfetti, VMD

**HOSPITAL NAME**

Leigh Valley Humane  
Society

**REFERRING VET**

Blue Pearl Wyomissing

**INVOICE**

47775

**DATE**

5/6/26

**PRESENTING CLINICAL SIGNS**

History: Echo to further evaluate a grade 5/6 heart murmur on pre-anesthesia exam prior to spay. Spay procedure was held. Owner noted that breeder informed her there was a slight heart murmur noted on a litter exam. BP: 158, 160, 161mmHg.

**ECHOCARDIOGRAM FINDINGS**

2D, m-mode, color flow and doppler imaging is available. Normal mitral valve leaflets with no obvious prolapse into the left atrial lumen. No obvious mitral regurgitation. Normal left atrial dimension. Normal LV diameter with adequate myocardial function. The LV wall thickness appears normal. The tricuspid valve appears mildly thickened and elongated with mild insufficiency seen. Elevated velocity. Moderate right atrial dilation. Right ventricular hypertrophy and remodeling indicative of pressure overload. Right ventricular dilation. Pulmonic outflow velocities are elevated. The pulmonic valve is difficult to visualize extensively; thickening suspected. A supravalvular narrowing is suspected on color flow. There is mild post-stenotic dilation of the main pulmonary artery and branches. Mild pulmonic insufficiency. The aortic valve appears to have normal morphology and mobility. Normal LVOT velocity. No AI. No obvious cardiac shunts are present. No pericardial or pleural effusion noted.

**CARDIAC CHART**

CANINE CARDIAC PARAMETERS	MR VMAX (m/s)	TR VMAX (m/s)	LA/AO (Boon method)	LA/AO (Heart Base; Swe)	FS (%)	EF (%)	EPSS (cm)
<b>NORMAL PARAMETER</b>	4.5-5.5	<2.7	1.3	<1.6	28-40	40-100	<0.6
<b>PATIENT</b>	NA	2.6	1.0	1.2	36	0	NM
CANINE CARDIAC PARAMETERS	HR (BPM)	AV VMAX (m/s)	PV MAX (m/s)	BODY WEIGHT (kg)	LA 2D short axis Base view (cm)	LVIDd Avg; 2D and m-mode short axis (cm)	LVIDs Avg; 2D and m-mode short axis (cm)
<b>NORMAL PARAMETER</b>	50-100	0.7-1.7	0.7-1.6	BELOW	BELOW	BELOW	BELOW
<b>PATIENT</b>	120	1.4	5.8	4.0	1.3	1.7	1.1
*Normal chamber parameters expressed as a mean value (SD)				3	1.27 (5.3)	2.46 (2.46)	1.36 (5.5)
<b>BODY WEIGHT DEPENDENT PARAMETERS</b>				5	1.40 (4.5)	2.74 (5.2)	1.60 (4.7)
*Note: All measurements based upon multi-modal images and methods. An average value is reported.				10	1.50 (3.8)	3.27 (3.5)	2.06 (3.1)
				15	1.83 (2.0)	3.71 (2.4)	2.43 (2.1)
				20	2.02 (1.9)	4.14 (2.2)	2.80 (2.0)
				25	2.18 (2.4)	4.48 (2.9)	3.10 (2.5)
				30	2.33 (3.3)	4.83 (3.9)	3.39 (3.4)
				35	2.48 (4.3)	5.17 (5.0)	3.69 (4.5)
				40	2.62 (5.2)	5.48 (6.1)	3.96 (5.4)
				50	2.88 (7.1)	6.07 (8.3)	4.46 (7.4)

**INTERPRETATION OF THE FINDINGS & FURTHER RECOMMENDATIONS**

The cause of the murmur is severe pulmonic stenosis. The PV appears thickened; however, visualization is limited. There is suspicion for a supravalvular component, which is highly unusual, and further imaging may be warranted. Regardless, the degree of obstruction is severe based



## PATIENT

Quinn Dougherty

## SPECIES

Canine

## BREED

Miniature Dashchund

## SEX

Female Intact

## AGE

10 months

## WEIGHT

8.8lbs

## INTERPRETED BY

Maggie Machen Lamy,  
DVM, DACVIM  
(Cardiology)

## IMAGING PERFORMED BY

Renee Trionfetti, VMD

## HOSPITAL NAME

Leigh Valley Humane  
Society

## REFERRING VET

Blue Pearl Wyomissing

## INVOICE

47775

## DATE

5/6/26

upon the velocity/pressure gradient across the pulmonic valve and the secondary hypertrophy and remodeling of the right ventricle. There is significant RA dilation and mild TR with mild tricuspid valve dysplasia as well. The risk for CHF in the future is elevated, and may limit lifespan. No other congenital abnormalities were visualized; however, small shunts or defects can be difficult to identify without a sedated bubble study in patients this young.

Referral for balloon valvuloplasty should be considered in this patient as the gold standard therapeutic option for this condition, which may improve long term outcome and delay onset of clinical signs (such as exertional syncope or right-sided congestive heart failure). If surgery is not elected, this patient's condition may limit lifespan, with many severe PS cases developing CHF by mid-life. Regardless, medical management with atenolol is recommended as below to decrease heart rate and lessen the obstruction as below. Monitor for development of associated clinical signs (collapse, abdominal distention, cough, labored breathing). **Mild exercise restriction is advised lifelong.**

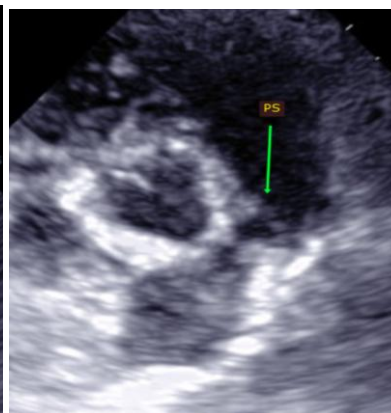
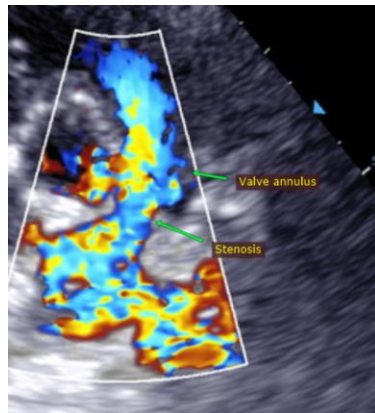
**Breeding this animal is not advised due to the genetic link of this disease.**

Anesthetic risk is mild to moderate at this time. **Avoid heart rate stimulating drugs such as atropine or glycopyrrolate unless absolutely necessary.** Avoid vasodilators such as acepromazine. Mild IV fluid restriction is advised. Cardiac protective drug choices (opioid/benzodiazepine premedication, propofol or alfaxalone induction, isoflurane gas) are recommended. Pre-oxygenate for 5-10 minutes prior to induction and recover in O<sub>2</sub> if possible. Monitor for arrhythmias, hypotension, and hypoxia both intra and post-operatively and intervene as necessary.

Plan: Institute atenolol to effect: 25mg tabs, ¼ tab PO BID to start (up-titrate to desired effect). Goal is to suppress heart rate <120-140bpm even with stress/activity. Baseline chest radiographs and ECG are recommended. Referral for evaluation and balloon valvuloplasty if desired.

If surgery is declined, recommend recheck echocardiogram in 6-12 months to assess for progression, response to medication.

## IMAGES





## PATIENT

Quinn Dougherty

## SPECIES

Canine

## BREED

Miniature Dashchund

## SEX

Female Intact

## AGE

10 months

## WEIGHT

8.8lbs

## INTERPRETED BY

Maggie Machen Lamy,  
DVM, DACVIM  
(Cardiology)

## IMAGING PERFORMED BY

Renee Trionfetti, VMD

## HOSPITAL NAME

Leigh Valley Humane  
Society

## REFERRING VET

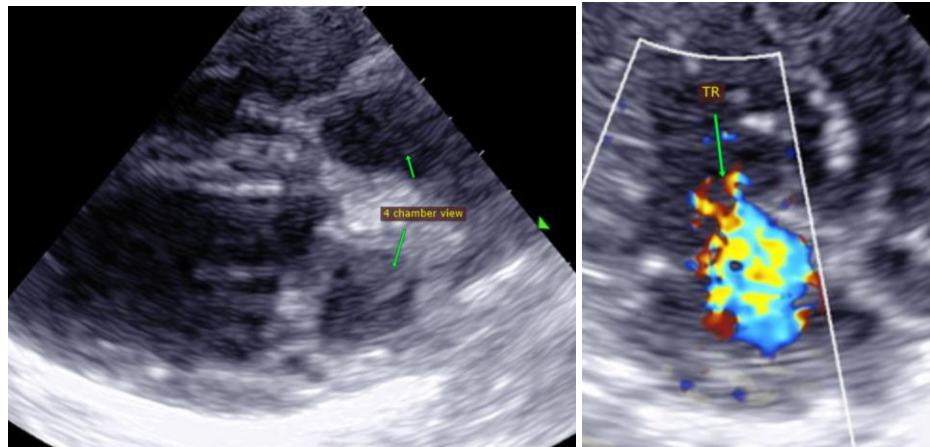
Blue Pearl Wyomissing

## INVOICE

47775

## DATE

5/6/26



**The information and recommendations provided are based on the images presented by the referring veterinarian. No evaluation can be communicated regarding pathology that was not visible in the image/video clips provided.**

Thank you for this referral. This report was generated using transcription software, and minor dictation errors may be present. If the clinical or image interpretation does not parallel your findings or if I can be of any further assistance, please contact me.

**Maggie Machen Lamy, DVM**

**Diplomate of the American College of Veterinary Internal Medicine (Cardiology)**

info@sonopath.com